

Finite Element Analysis of Bone Remodeling: Resident's Ridge Formation in Femoral Condyle

Yusuke TAKAHASHI, Shigehiro HASHIMOTO

Biomedical Engineering, Department of Mechanical Engineering,
Kogakuin University, Tokyo, 163-8677, Japan
shashimoto@cc.kogakuin.ac.jp <http://www.mech.kogakuin.ac.jp/labs/bio/>

and

Hiromichi FUJIE

Human Mechatronic Systems, Faculty of System Design,
Tokyo Metropolitan University, Tokyo, Japan fujie@sd.tmu.ac.jp

ABSTRACT

The Resident's ridge has been used as a landmark at surgical operations to reconstruct the anterior cruciate ligament, although the mechanical background of the ridge has not been interpreted. The formation of Resident's ridge on the human femur has been analyzed under a hypothesis that the ridge is formed through interstitial fluid flow-induced bone remodeling in the present study. A two-dimensional analytical model has been constructed with 228 x 20 cortical bone elements. A tensile force of 485 N was applied to the surface of attachment area of the ligament with an inclination angle of 7.6 degree to the surface, while both the ends of the model were fixed. Interstitial fluid flow rate and compressive strain in the model in response to the force application have been calculated with a finite element analysis software. Based on the flow rate or compressive strain the bone shape near the ligament attachment was remodeled until equilibrium state was attained. Results revealed that high flow rate was observed at the end of ligament attachment while almost negligible flow rate was observed at the center of ligament attachment. Moreover, calculated bone shape based on the flow rate distribution was similar to actual bone shape near the ligament attachment. It was, therefore, suggested that the Resident's ridge formation can be explained by interstitial fluid flow-induced bone remodeling.

Keywords: Biomedical Engineering, Finite Element Analysis, Bone Remodeling and Resident's Ridge Formation.

1. INTRODUCTION

The anterior cruciate ligament (ACL), which is one of four major ligaments in the knee, is a crucial structure for knee stability. Since the ACL is the most liable to failure and rupture in the four ligaments in daily and sports activities, surgical reconstruction is often applied to restore the ligament function. The Resident's ridge: a bony ridge near the femoral

attachment of the ACL (Fig. 1) [1], has been used as a landmark at surgical operations to reconstruct the ligament, although the mechanical background of the ridge formation remains unclear. To explain the ridge formation, we have proposed a hypothesis that the ridge formation is occurred due to bone remodeling in response to ACL force-induced interstitial fluid flow [2]. Following the hypothesis, the formation of the Resident's ridge has been analyzed with the finite element method in the present study.

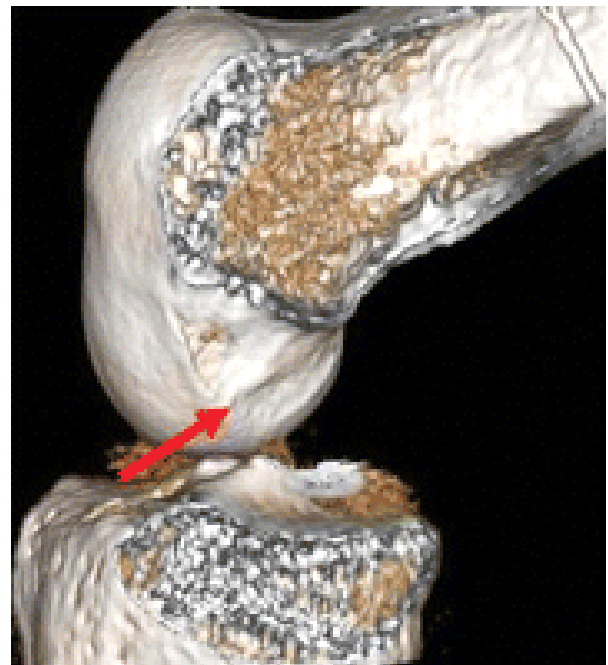

Fig. 1: Resident's ridge (shown by red arrow) on the posterior-superior border of the lateral wall of the intercondylar notch of the human femoral condyle [6].

2. METHODS

Finite Elements

A computational 2-D model of a cortical bone ($22.8 \text{ mm} \times 2.0 \text{ mm}$) near the ACL femoral attachment was created using pixel-based finite elements in a FEM software (Abaqus 6.7, Simulia, USA) as shown in Fig.2. The size of each element was of $0.10 \text{ mm} \times 0.10 \text{ mm}$. The bone was assumed to be homogeneous and isotropic material with Young's modulus of 20 GPa [3] and Poisson's ratio of 0.3. Moreover, the bone was assumed to be permeable for water with the permeability of 0.001 Pa s [4].

Calculation

A tensile force corresponding to 485 N of ACL force [5] has been applied to the bone surface of 7.6 mm in width [6] at the center of the model with an inclination angle of 7.6 degree to the surface [Matsuda], while both the lateral ends of the model was fixed. Interstitial fluid flow rate and compressive strain in the model in response to the force application was calculated. Referring to a bone remodeling analysis by Tsubota et al. [2], bone surface movement was performed by adding a new element on a surface if the flow rate in an element was higher than $6.0 \times 10^{-2} \text{ mm/s}$. Simultaneously, the element was eliminated if the flow rate was lower than $0.1 \times 10^{-2} \text{ mm/s}$. The procedure including the flow rate analysis and bone surface movement was repeated until equilibrium state was attained. For comparison, strain-induced bone remodeling analysis was also performed under a condition that element addition was performed in response to compressive strain ($> 2.0 \times 10^5$) and element elimination was performed in response to tensile strain ($> 3.5 \times 10^5$), referring to a previous study by Fujie [7].

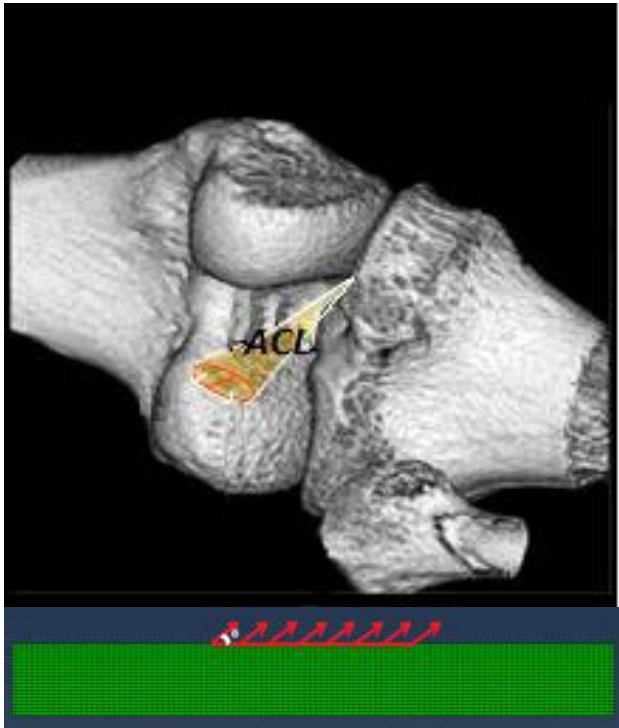


Fig. 2: 3-D CT image of the human knee including the femoral attachment of the ACL and 2-D model of the femoral cortical bone with the ACL force applied to the ACL attachment area.

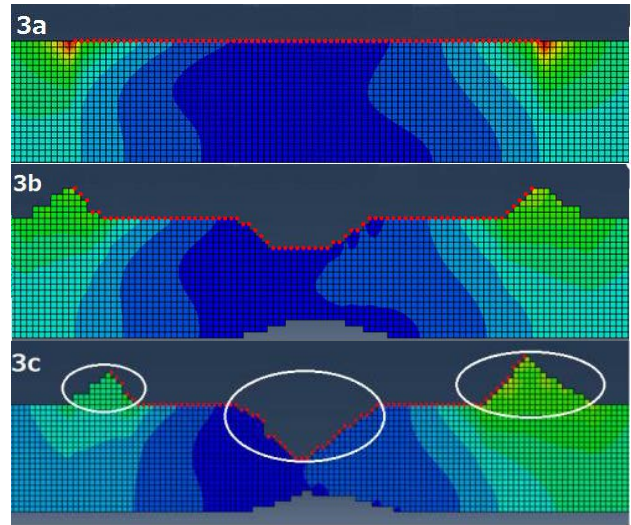


Fig. 3: Interstitial fluid flow-induced bone remodeling with flow rate distribution (a: first step before remodeling, b; 5th step of remodeling, c; 10th (final) step of remodeling)

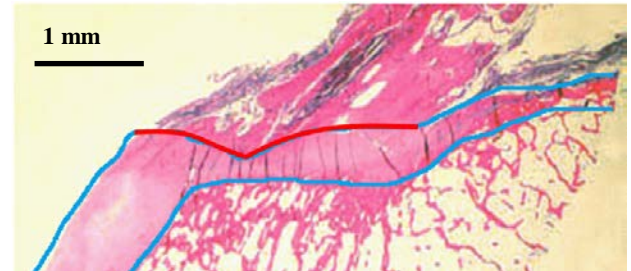


Fig. 4: Histological (HE) observation of the human femoral ACL attachment.

3. RESULTS

Results revealed that the flow rate was very high at both sides of ligament attachment while it was almost negligible at the center of ligament attachment (Fig. 3a). The bone surface structure near the ACL attachment was gradually remodeled during the flow rate-induced remodeling calculation (Fig. 3b), and finally reached to an equilibrium state (Fig. 3c). Note that the anterior side of the ACL attachment (right circle in Fig. 3c) was remodeled from a flat shape to a Resident's ridge-like structure of 0.8 mm in height and 1.4 mm in width. Moreover, another ridge formation was observed at the other side of the ACL attachment (left circle in Fig. 3c) while a bone resorption was observed near the center of the ACL attachment (center circle in Fig. 3c). In comparison, equilibrium state was not attained in the strain-induced bone remodeling (Fig. 4). At the 10th remodeling calculation, a broad but low ridge of 0.4 mm in height and 4 mm in width was observed at the anterior side of the ACL attachment. Note that bone absorption was observed near the center of the attachment.

4. DISCUSSION

Calculation of the flow rate-induced bone remodeling was reached to an equilibrium state that clearly indicates a Resident's ridge-like bone structure. Moreover, another ridge formation at the other side and bone resorption near the center were observed within the ACL attachment. These remodeled structures obtained in the bone remodeling analysis were similar to actual bone structure. Note that the quantitative results were dependent on the analytical condition, however, the trend of the obtained results as to ridge formation and bone resorption were identical regardless of the condition. It was, therefore, suggested that the Resident's ridge formation and associated bone structure changes can be explained by interstitial fluid flow-induced bone remodeling. Although ridge-like bone formation was observed at not only anterior side but also posterior side of the ACL attachment, flow direction was different; outlet flow in the anterior side versus inlet flow in the posterior side. This difference in flow direction may cause a difference in bone formation. Moreover, the fluid flow rates of remodeling condition were not based on experimental results. Further and more detailed studies are required for the analysis of the Resident's ridge formation, including an *in vitro* study as regard with osteocyte response to interstitial flow.

5. CONCLUSION

A two-dimensional analytical model has been constructed with 228 x 20 cortical bone elements. A tensile force of 485 N was applied to the surface of attachment area of the ligament with an inclination angle of 7.6 degree to the surface, while both the ends of the model were fixed. Interstitial fluid flow rate and compressive strain in the model in response to the force application have been calculated with a finite element analysis software. Based on the flow rate or compressive strain the bone shape near the ligament attachment was remodeled until equilibrium state was attained. Results revealed that high flow rate was observed at the end of ligament attachment while almost negligible flow rate was observed at the center of ligament attachment.

6. ACKNOWLEDGMENT

This work was supported by a Grant-in-Aid for Strategic Research Foundation at Private Universities from the Japanese Ministry of Education, Culture, Sports and Technology.

REFERENCES

- [1] K. Shino, T. Suzuki, T. Iwahashi, T. Mae, N. Nakamura, K. Nakata and S. Nakagawa, "The Resident's Ridge as an Arthroscopic Landmark for Anatomical Femoral Tunnel Drilling in ACL Reconstruction", **Knee Surgery, Sports Traumatology, Arthroscopy**, Vol. 18, No. 9, 2010, pp. 1164-1168.
- [2] K. Tsubota, T. Adachi and Y. Tomita, "Functional Adaptation of Cancellous Bone in Human Proximal Femur Predicted by Trabecular Surface Remodeling Simulation Toward Uniform Stress State", **Journal of Biomechanics**, Vol. 35, No. 12, 2002, pp. 1541-1551.
- [3] J.C. Lotz, T.N. Gerhart and Hayes WC, "Mechanical Properties of Metaphyseal Bone in the Proximal Femur", **Journal of Biomechanical Engineering**, Vol. 113, No. 4, 1991, pp. 317-329.
- [4] E.A. Nauman, K.E. Fong and T.M. Keaveny, "Dependence of Intertrabecular Permeability on Flow Direction and Anatomic Site", **Annals Biomedical Engineering**, Vol. 27, No. 4, 1999, pp. 517-524.
- [5] E.H. Chen and J. Black, "Materials Design Analysis of the Prosthetic Anterior Cruciate Ligament", **Journal of Biomedical Materials Research**, Vol. 14, No. 5, 1980, pp. 567-586.
- [6] M.L. Purnell, A.I. Larson and W. Clancy, "Relationships to Critical Bony Landmarks Using High-resolution Volume-rendering Computed Tomography", **American Journal of Sports Medicine**, Vol. 36, 2008, pp. 2083-2090.
- [7] H. Fujie, K. Nakata and K. Shino, "Resident's Ridge Formation Due To ACL Force-Induced Bone Remodeling". **Japanese Clinical Biomechanics and Related Research**, ORS 2013 Annual Meeting, Poster No: 1383